

Article ► Intermittent Central Suppression Suffered After a Rough Landing on a Bicycle

Eric S. Hussey, OD, Spokane, Washington

ABSTRACT

Background: Seth, a 16-year-old male student-athlete, suffered a concussion during trail riding in 2014 when his bike came apart during a jump. The patient's occupational therapist referred him for a vision examination and therapy following vestibular therapy. Unresolved post-concussion symptoms included headaches, problems seeing the ball in sports, and reading problems reminiscent of "dyslexia."

Case Report: The initial specific examination of Seth's binocularity 4 months post-concussion showed intermittent central suppression (ICS). Since all symptoms began post-trauma, it is more likely than not that the suppression was a result of the head injury. Vision therapy concentrated on eliminating the ICS, including using rapid alternation with liquid crystals. Therapy was in-office, started slowly in order to respect his post-concussion symptoms, and also included standard eye movement and vergence therapies. Thirty-seven visits eliminated the suppression, confirmed at a progress evaluation 6 months post-therapy.

Conclusion: Following therapy, the patient's symptoms were resolved, and he was able to return to riding his bike.

Keywords: binocularity, concussion, intermittent central suppression, reading problems

A Rough Landing

Seth is an athlete, and Seth is smart. In 2016, he was in ROTC at a local university and was thinking about medical school. At 16 years old, Seth was taking advanced placement classes in high school and was also working at a pizza restaurant. Seth's main athletic activities were – and still are – weight training and bike riding. His bicycle is still his main form of transportation. Although Seth uses a helmet properly when riding, one of the things that he did not expect as he was trail riding near his home in June 2014 was that as he jumped his trail bike over some terrain, the front fork and wheel of the bike would fall off in mid-air, apparently from faulty assembly at the factory.

Since he was alone, it is unknown how long Seth was unconscious following the accident. However, he somehow made his way home and was diagnosed at the ER as having a concussion. Other health history was remarkable only for

Dr. Hussey talking about Seth's case.

a prior appendectomy. Seth had physical and occupational therapy, including vestibular therapy, and it was the local rehabilitation hospital therapists who referred him for visual evaluation in October 2014. He had a routine eye examination at a local medical eye clinic a month prior to examination in our clinic. Since we had the information from the prior examination that eye health and the visual field were normal, we

Table 1. Vectographic Tests. nfd=near fixation disparity on Borish near card; dia=diamond target on Borish near card (modified with polarizers); dac=distance acuity targets; dcd=distance clock dial; dfd=distance fixation disparity; R=suppression of right eye's image, L=suppression of left eye's image, Alt=alternates, L>R=alternates, but suppresses left eye's image much more than right eye's image.

		Initial Visit	Prog 1, 20% improvement	Prog 2, 40% improvement	Prog 3, 90% improvement	Prog 4, 99% improvement	6 Month ReEx
BCVA, vectographic chart	OD	20/30	20/25-	20/25+	20/20	20/20+	20/20+
	OS	20/40	20/30-	20/30+	20/20	20/20	20/20
Vectographic Targets showing ICS* <small>*not all subtests were done at each visit</small>	Alt: nfd, dia, dcd L>R: dac	L>R: dia, dac Alt: nfd, dcd L: dfd	Alt: dia, dcd dac: bilateral presentation only	No ICS, but also no stereo	No ICS	No ICS	
ICS periodicity suppressed diamond (avg sec) not suppressed	2/2	1.5/3	1.5/7	No ICS	No ICS	No ICS	
Distance stereo, vectographic	0/4	0/4	0/4	0/4	4/4	4/4	

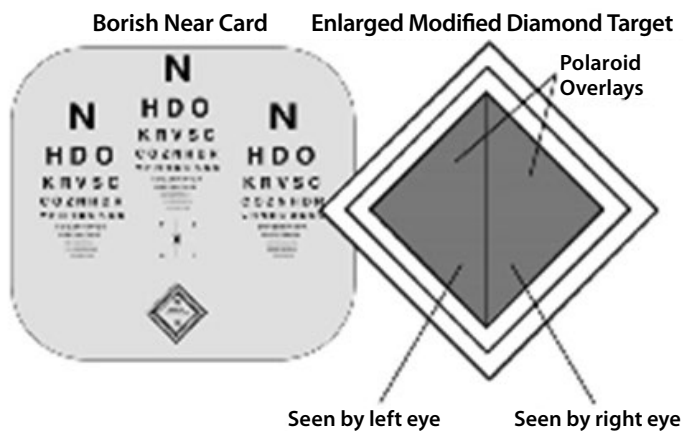


Figure 1. Schematic of (modified) Borish Near Card

concentrated on evaluating Seth's binocularity. I did do both retinal and anterior segment examinations that showed very normal and healthy eyes, as well as confrontation fields, eye movement range, and cover test—all normal. Near point of convergence (NPC) was reduced (12/14").

Seth's complaints at our initial encounter included headaches, difficulty focusing, twitching of his right eye, dizziness, trouble seeing the ball coming at him in sports, and a group of reading difficulty symptoms: skipping words, re-reading lines, words moving and disappearing, and, unsurprisingly, memory problems.

Testing of Seth's vision and binocularity followed our standard vectographic testing¹

and is summarized in Table 1. On arrival, Seth saw 20/25- OD and 20/30 OS without lenses. His manifest distance lens prescription of +0.50 sph OD and +0.75 sph OS didn't improve acuity, and in fact, as fatigue set in and with the reduced contrast of vectographic letters, his acuities dropped to 20/30 and 20/40. He could not respond to near vergence testing, and he actually could not appreciate diplopia on phoria testing after near binocular crossed-cylinder testing.

Sensory testing of binocularity showed intermittent central suppression (ICS) on a number of vectographic targets.¹ The timing of the suppression period at near showed the "classic" repetitive periodicity of about two seconds of bilateral sight followed by a two-second-or-so suppression of either eye's picture,² and occasionally he showed a bilateral dropout of central vision, all on near testing done with the modified Borish card (Figure 1).

At distance, when he was looking at the vectographic acuity letters, Seth described the left eye's image as looking like "fireworks," with letters disappearing and coming back. Distance stereopsis as well as near stereopsis with the Wirt test was nil. The Developmental Eye Movement Test, using the 13-year-old norms, was at the 1st percentile level—in a 16-year-old.³ I had not

seen Seth prior to his accident, but since his symptoms started post-trauma, I felt reasonably confident in saying that the suppression and other visual problems were likely primarily, if not entirely, a result of the trauma.

We ordered the hyperopic prescription in glasses for Seth; then, as is my habit, I wrote a report to Seth and his parents and copied the report to the referring occupational therapist. After outlining my findings, the summary paragraph of my report suggests that if they decide that they would like to do therapy for the suppression and the other problems, please give us a call, which they did later in the month.

In our therapy, we follow the counsel of Louis Jaques, OD from the 1950s that the first and most important job is to treat the suppression.⁴ With all patients, we try to work within their abilities, but with trauma that becomes even more important. Despite Seth's young age and physical toughness, we started with a very limited schedule. We were often limited in what we could do because Seth wasn't feeling well or had a migraine. Early on, office visits and procedures were limited. Eye movement procedures were limited to placing tees in the rotator at slow speed and monocular saccades using a computer presentation program. Bilateral line drawings such as a VO star were sometimes impossible. One advantage we have over Louis Jaques in working to eliminate suppression is that although we use stereoscope drawings, similar to his techniques, we also have easy access to electronic rapid alternate occlusion with liquid crystals.⁵ With the alternation as the mechanism to reduce suppression, we could have Seth color in a simple drawing just sitting at a desk and begin to build binocularity. After 10 therapy visits at an every-week to every-two-weeks schedule, I evaluated Seth's progress and found acuities at 20/25- OD and 20/30- OS. He showed some change in the suppression. Now, suppression periods were 1 to 2 seconds long, and binocular (or bilateral-

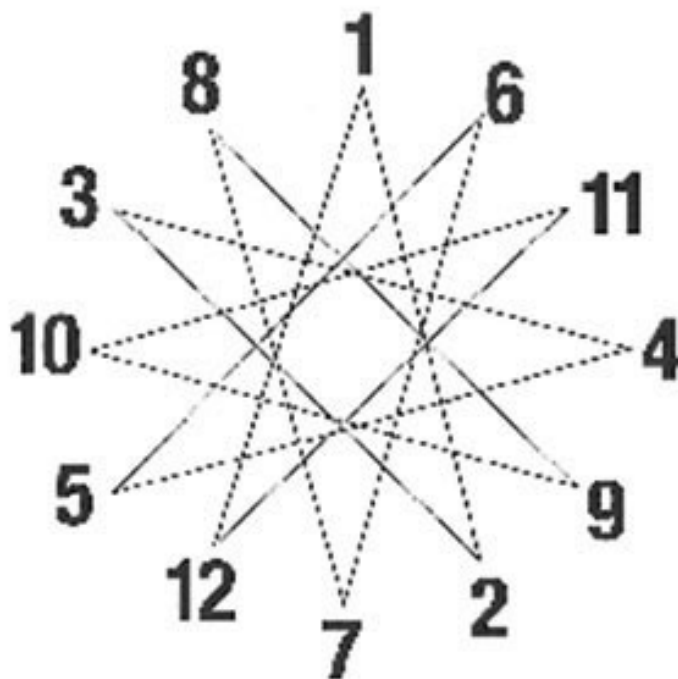


Figure 2. VO3 star target

sight) periods were up to four seconds long. Seth could respond to near vergence testing at this evaluation, showing mild convergence insufficiency. However, he still suppressed on near phorias.

A practice that I started some years ago is to give patients a generalized rough estimate of the change in the suppression at each progress evaluation. I explain that the estimate is very sloppy since there are a number of subtests involved, but I estimated Seth's improvement at about a 20% decrease in the suppression. Additionally, we were getting more done at each 40-minute session. Virtually all therapy was done in-office.

Seth improved in how much he could do in therapy, so we responded by increasing what we asked of him. Rapid alternate occlusion continued to be part of the therapy, and starting each session with coloring while using the alternate occlusion goggles continued to "set up" Seth's vision to be able to do therapy. Plus, it was something that he could do without side effects. Computer saccades could be accomplished, and we moved into more hand-directed eye movements such as tracing the lines on a VO3 Star target (Figure 2). At the

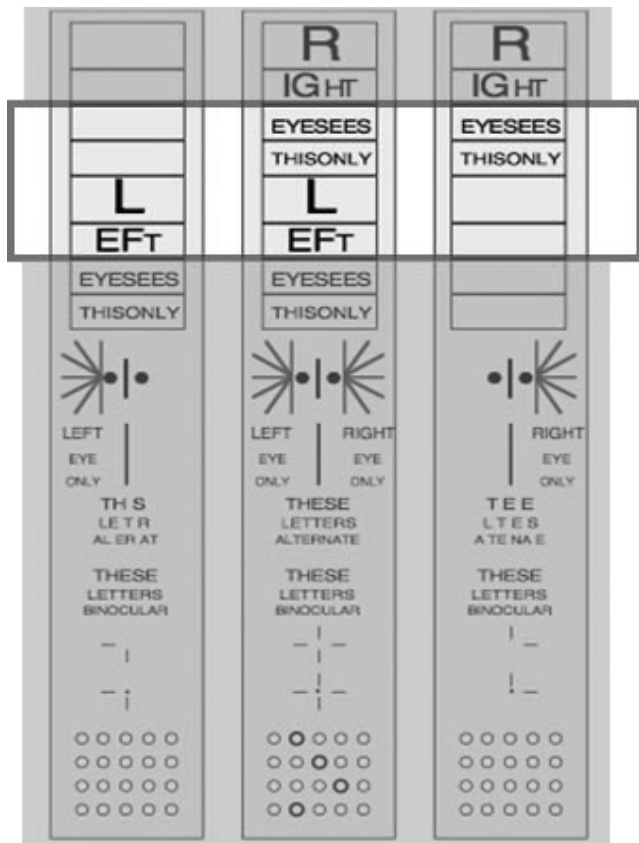


Figure 3. Schematic of distance vectographic chart showing “bilateral acuity” framing

next progress evaluation after an additional six sessions, I estimated the improvement in the suppression at 40%, noting that binocular periods were now commonly up to 5 seconds long. Occasionally, Seth showed a ten-second period of no loss of central vision on the near Borish target. That means that where originally every two seconds or so one eye’s picture would drop out, allowing aiming errors as well as rivalry with perceptual filing-in,⁶ now he would spend up to 10 seconds with both eyes seeing simultaneously and so was able to process the visual signal relatively accurately for those ten seconds. He could see diplopia on phorias at near, but it developed slowly. Seth now only suppressed on distance acuity letters when they were scrolled so that the left lower letters and the right upper letters were seen in the same projected frame (Figure 3). However, other distance targets still showed alternation. Acuities were now 20/25+ OD and 20/30+ OS.

Spacegoggle demonstration.

As Seth progressed, we slowly replaced coloring at the desk with “Colors” (see appendix) in the stereoscope visual environment while using rapid alternation. In doing the alternation, we are always adjusting the frequency and balance of alternation (see video for a demonstration). As those adjustments are made, we maximize the bilateral sight periods and minimize the fixation drift during a “Colors” drawing task (Appendix A). Most of Seth’s work was done at 5.0 Hz direct alternation with even 50-50 balance. However, on a given day and depending on how he was responding, frequencies and balances that gave us more binocularity and less suppression included 4.0 Hz/50-50 balance, 4.0 Hz/balance shifted to R side, 4.0 Hz/balance shifted to L side, 4.5 Hz/50-50 balance, 4.8 Hz/50-50 balance, and 5.0 Hz balance shifted to L side. We also started working on the single aperture (aperture rule) to build some stamina in vergence. We also used simple anaglyphic shapes drawn in the computer, printed on acetate, then backlit with a wall-mounted light drawing table to try to develop some stereo appreciation.

At the next evaluation as we passed thirty-five visits, the intermittent central suppression was not easily elicited. The only nagging suppression-related finding was that Seth still showed no stereo on the distance vectographic chart. Acuities were now 20/20 OD, OS on the distance vectographic chart. At that time, Seth reported that he could “read for hours with no fatigue” and that he remembered what he

was reading. He also described how normal real-world depth perception would come “in waves” transiently in different parts of his visual field, and those parts shifted around. We continued with the same therapy procedures, but now we were able to do diplopia training using dissociated rotations with vertical and horizontal dissociating prisms and the rotator. I re-evaluated Seth just seven visits later because a parked motorist threw her door open in front of Seth while he was riding his bike. Fortunately, there was no damage to his head, and at this evaluation at long last he was able to find the stereo rings at distance (90 seconds of arc), albeit slowly. He also showed no suppression on any of the polarized targets, distance or near. At near, he still could only manage 200 arcseconds on the Wirt test (#2 on dots).

We were able to do two more therapy visits, then we saw Seth at the 6-month mark for a progress evaluation. Seth still showed no suppression on the vectographic test targets. The Maples pursuit test was normal, and NPC was to the nose. He still showed 90 seconds of stereo at distance. Given a little time, he scored 40 arcseconds on the Wirt dot test. To test him further, we showed him the Randot 2 test, where he scored #11 (16 arcseconds) and managed to see one target on the random dot (“global stereopsis”) section at 125 arcseconds. The DEM, not fully valid because of his age, improved from the 1st percentile level (vertical and horizontal) including lots of finger use to the 40th and 45th percentiles, respectively (12-year-old norms). Seth is now at college in ROTC taking courses including chemistry and nutrition and is still able to read “for hours.”

Conclusion

Thirty-seven vision therapy visits eliminated Seth’s trauma-induced ICS, confirmed at a progress evaluation 6 months post-therapy. With the elimination of the ICS, symptoms were alleviated, and Seth now refers to himself as “back to normal.” That includes real-world depth perception, memory, lack of headaches...and he’s back to riding his bike.

References

1. Hussey ES. Examination of binocular sensation over time with routine testing. *J Behav Optom* 2000;11(2):31-4. <http://bit.ly/2uCACbQ>
2. Hussey ES. Temporal characteristics of intermittent central suppression. *J Behav Optom* 2002;13(6):149-52. <http://bit.ly/2w62bd8>
3. Garzia RP, Richman JE, Nicholson SB, Gaines CS. A new visual-verbal saccade test: The Developmental Eye Movement test (DEM). *J Amer Optom Assoc* 1990;61(2):124-35. <http://bit.ly/2uCnl2V>
4. Jaques L Sr. *Corrective and Preventive Optometry*. Globe Printing, 1950. <http://bit.ly/2uUABLA>
5. Hussey ES. Remote treatment of intermittent central suppression improves quality of life measures. *Optometry J Amer Optom Assoc* 2012;83(1):19-26. <http://bit.ly/2wXimGC>
6. Hussey ES. Is Anti-Suppression the Quest for Visibility? *Optom Vis Perf* 2015;3(1):33-41. <http://bit.ly/2hZ0FUN>

Correspondence regarding this article should be emailed to Eric S. Hussey, OD, at spacegoggle@icloud.com. All statements are the author's personal opinions and may not reflect the opinions of the representative organizations, ACBO or OEPP, Optometry & Visual Performance, or any institution or organization with which the author may be affiliated. Permission to use reprints of this article must be obtained from the editor. Copyright 2017 Optometric Extension Program Foundation. Online access is available at www.acbo.org.au, www.oepf.org, and www.ovpjournal.org.

Hussey ES. Intermittent central suppression suffered after a rough landing on a bicycle. *Optom Vis Perf* 2017;5(4):201-6.

Appendix A: Colors

Normally, chieroscopic tracings are done in the therapy room with the patient looking into a stereoscope and with a line drawing showing in front of one eye and a blank field in front of the other—often called monocular fixation in a binocular field (MFBF)—with the instruction to trace the lines of the picture, perhaps including instructions to draw top to bottom and left to right to reinforce the directions of the written language in English. If we want to work on suppression, however, two things are required: bilateral sight and motion.^{5,6} So, in Colors, rather than having the patient trace lines, we have them color things in. We start with simple shapes to color in (Figure 4). Then the explicit instruction is NOT to trace the lines, but to color the shapes in with a colored pencil on the blank side with a scrubbing/coloring motion. If the shapes move, they move. Don't worry about it. We do one coloring using the right hand with the blank side on the right and then flip the stimulus situation over and do another one using the left hand with the blank side on the left. In trauma, we start simple and progress toward more complex shapes, always working within the stamina bounds of the patient. Then, as the patient can accomplish the task, we add rapid alternation to drive the visual neurology harder. As with all neurology, change takes time and repetition, so we make Colors one of our standard therapy procedures done at each visit.

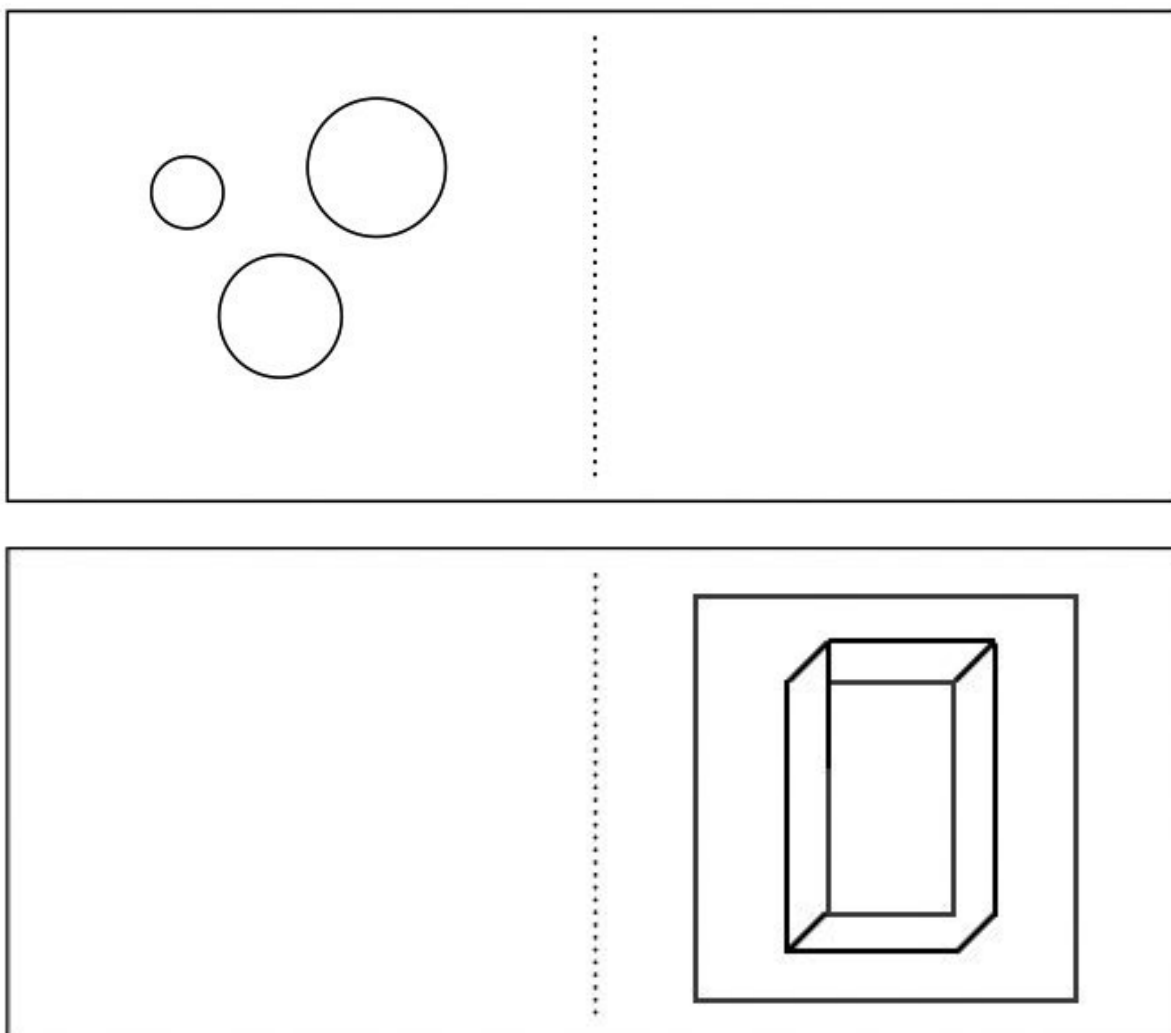


Figure 4. Colors targets